

The "Point of Care" section answers everyday clinical questions by providing practical information that aims to be useful at the point of patient care. The responses reflect the opinions of the contributors and do not purport to set forth standards of care or clinical practice guidelines. This month's contributors are from the University of Manitoba's faculty of dentistry.



QUESTION 1

What additional precautions should I take when bonding to severely fluorotic teeth?

Background

Restorative dentists and orthodontists have described severely fluorotic teeth as the most difficult surface for bonding.^{1,2} The difficulty arises from the composition of the enamel of such teeth, which has an acid-resistant, hypermineralized outer layer. As a result, it is very difficult to mechanically treat the surface with conventional 37% phosphoric acid to allow for effective bonding.³ Further, the subsurface of the fluorotic enamel has defects that exacerbate the difficulty of etching the surface. Fluorosis manifests as irregular and unsightly brown or white opaque lines, pits, striations or cloudy areas (**Fig. 1**). The esthetic appearance of the dentition is often a concern for patients with fluorosis, and they frequently receive composite or laminate veneers, or they undergo microabrasion or bleaching.

Scanning electron microscopy has been used to compare fluorotic and nonfluorotic teeth previously treated with 37% phosphoric acid. These studies confirmed that the fluorotic teeth had fewer irregularities from the etchant; they also demon-

strated the unpredictability of treating fluorotic enamel.⁴⁻⁶

Faced with the challenge of bonding to this type of tooth surface, clinicians have the option of prolonging treatment with 37% phosphoric acid, performing microabrasion of the enamel, using an adhesion promoter or combining all 3 methods.

Despite the clinical difficulty of bonding to fluorotic enamel, there is a paucity of clinical studies in the literature examining the various methods of bonding to this surface. The following summary includes details from the few published studies available.

Microabrasion

Microabrasion of the enamel, in combination with etching, has been said to improve bond strength.⁶ Microabrasion is accomplished with aluminum oxide or silicone carbide powder, which is directed toward the tooth surface for 3–5 seconds with an air-abrasion unit (**Fig. 2**). The treatment also involves use of a rubber dam and high-volume suction (**Fig. 3**).

Microabrasion has certain drawbacks, including damage to the enamel, the need for a rubber dam and clamp, potential ingestion of the powder particles, potential for facial trauma from the particles, allergy to the powder material, an increase in chair time and costs, and patient discomfort.

Use of Adhesion Promoter

Use of an adhesion promoter is a more predictable means of chemically bonding to an enamel structure with fluorosis or to primary teeth. The promoter consists of a primer (an aqueous solution of hydroxyethylmethacrylate [HEMA]) and a polyalkenoic acid, which is believed to assist in controlling moisture. The primer allows the resin layer to flow over or wet the etched surface. The adhesive consists of a Bis-GMA (bisphenol A glycidyl methacrylate) and HEMA resin combined with a mixture of amines, which allows for quick

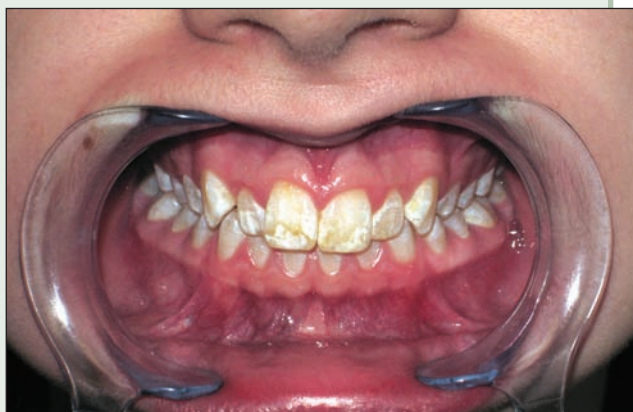

Figure 1: Patient with severe dental fluorosis who is concerned about pitting and unsightly brown and white lines and striations.




Figure 2: Microabrasion unit.

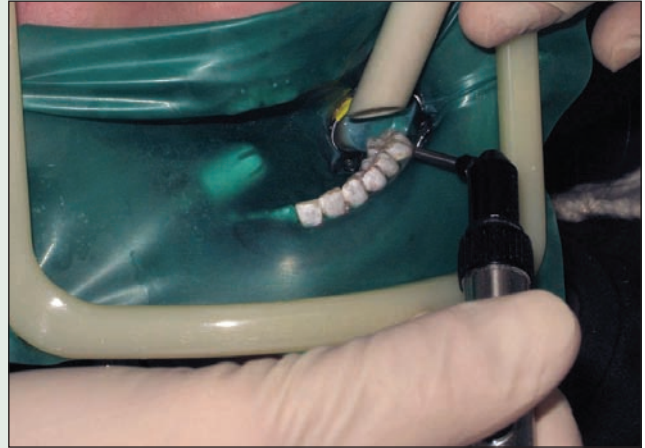

Figure 3: Patient with dental fluorosis undergoing microabrasion under high-volume suction and rubber dam before bonding orthodontic brackets to increase mechanical retention.

(10-second) curing with a visible-light curing unit. This chemical adhesion is thought to result in less microleakage and allows for a superior hermetic seal.

A recent prospective study examined bond failure for orthodontic attachments bonded to severely fluorotic teeth with an adhesion promoter (Scotchbond Multipurpose Plus Primer, 3M/Unitek, Monrovia, Calif.) in combination with acid etching, with and without the additional step of microabrasion.⁷ The authors found no statistically significant difference between the 2 groups, which suggests that an adhesion promoter allows successful bonding to fluorotic enamel without the additional step of microabrasion.

Conclusions

Bonding to fluorotic enamel is challenging because of the difficulty of mechanically roughening the surface with conventional 37% phosphoric acid etching. Prolonging the application time for the etchant or using microabrasion may increase mechanical retention and bond strength. Chemical bonding to this surface is another alternative that is more predictable and just as clinically effective. ♦

References

1. Fejerskov O, Manji F, Baelum V. The nature and mechanisms of dental fluorosis in man. *J Dent Res* 1990; 69(Spec No):692-700.

2. Miller RA. Bonding fluorosed teeth: new materials for old problems. *J Clin Orthod* 1995; 29(7):424-7.

3. Denbesten PK, Thariani H. Biological mechanisms of fluorosis and level and timing of systemic exposure to fluoride with respect to fluorosis. *J Dent Res* 1992; 71(5):1238-43.

4. Hoffman S, Rovelstad R, McEwan WS, Drew CM. Demineralization studies of fluoride-treated enamel using scanning electron microscopy. *J Dent Res* 1969; 48(6):1296-1302.

5. Kochavi D, Gedalia I, Anaise J. Effects of conditioning with fluoride and phosphoric acid on enamel surfaces as evaluated by scanning electron microscopy and fluoride incorporation. *J Dent Res* 1975; 54(2):304-9.

6. Opinya GN, Pameijer CH. Tensile bond strength of fluorosed Kenyan teeth using the acid etch technique. *Inter Dent J* 1986; 36(4):225-9.

7. Noble J, Karaiskos N, Wiltshire WA. In vivo bonding of orthodontic brackets to fluorosed enamel using an adhesion promoter. *Angle Orthod* 2008; 78(2):357-60.

THE AUTHORS



Dr. James Noble is a part-time clinical instructor in the division of orthodontics, faculty of dentistry, University of Manitoba, Winnipeg, Manitoba. He is also a staff orthodontist at Bloorview Kids Rehab in Toronto, Ontario, and maintains a private practice in orthodontics in Toronto. Email: drjamesnoble@gmail.com



Dr. Nicholas E. Karaiskos maintains a private practice in orthodontics in Ottawa, Ontario.



Dr. William A. Wiltshire is a professor in and head of orthodontics and head of the department of preventive dental sciences, University of Manitoba, Winnipeg, Manitoba.

QUESTION 2

How do you predict the eventual amount of spacing or crowding that will occur in a child in the mixed dentition stage?

Background

In caring for patients in the mixed dentition stage, knowledge of the eventual mesiodistal width of the succedaneous canines and premolars may assist the clinician with diagnosis and treatment planning. Such information may be useful if early orthodontic treatment is to be initiated, if the permanent teeth are very large or crowding is severe and serial extraction is being contemplated, or if a deciduous tooth has been lost prematurely and a space maintainer or regainer appliance is being recommended to gain space or hold the teeth in their current position.

Three analyses can be used to assess patients in the mixed dentition stage: prediction of tooth size from radiographs, estimation of tooth size from proportional tables, and the Tanaka-Johnston method of calculating eventual tooth size.

With any of these techniques, the teeth should be screened for anatomic anomalies during the clinical examination or by evaluating plaster casts or radiographs. Also, if the patient is in the late mixed dentition stage and the premolar or canine has erupted on one side, the mesiodistal dimension of this tooth can be assumed to reflect the mesiodistal dimension of the unerupted contralateral tooth.

Predicting Tooth Width from Radiographs

Measurement of the mesiodistal dimension of teeth from radiographs requires an image that is not distorted. Periapical radiographs are therefore superior to panoramic radiographs. Magnification of the image can be compensated for by estimating the degree of magnification of teeth that have already erupted. However, because a radiograph is a 2-dimensional image, size cannot be estimated for teeth that are rotated (**Fig. 1**); therefore, this technique is not as commonly used. In addition, errors in radiographic technique may cause distortion.

The use of radiographs to predict the width of unerupted teeth may gain popularity with the increasing use of cone-beam computed tomography for orthodontic patients, as the 3-dimensional image generated by this method may be more accurate.

Estimation of Tooth Size from Proportional Tables

Estimation of tooth size from proportional tables involves calculating the size of the total mesiodistal tooth structure of one arch and subtracting this from the space available in that arch.

The sum of the mesiodistal dimensions of the mandibular incisors is calculated first. The mandibular incisors are used because their size correlates better with the size of the maxillary canines and premolars than does that of the maxillary incisors (which is extremely variable). This sum is then compared with values in a proportional table generated from previous direct measurement of dental casts; the proportional table is then used to predict the size of the unerupted mandibular and maxillary canines and premolars.¹

Next, the space available is determined by dividing the arch into 4 straight-line segments, each of which is measured with a Boley gauge: (1) mesial surface of the first permanent molar to distal surface of the lateral incisor, (2) distal surface of the lateral incisor to mesial surface of the central incisor, (3) mesial surface of the same central incisor (a diastema may be present) to distal surface of the contralateral lateral incisor and (4) distal surface of the contralateral incisor to mesial surface of the contralateral first permanent molar. These 4 values are then summed. This represents a static space analysis, but a dynamic space analysis is also possible. It involves projecting the newly aligned positions of the malaligned teeth and then

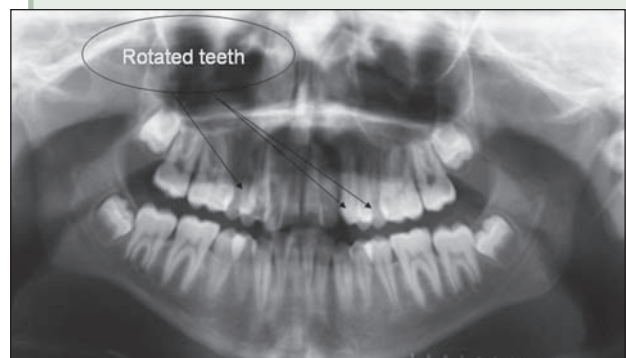
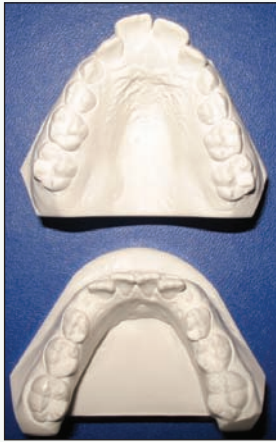

Figure 1: Radiograph depicting rotated premolar teeth. The rotation leads to inaccuracy in predicting the mesiodistal width of the premolars.



- Mandibular anterior mesiodistal width = $6.9 + 6.0 + 6.2 + 6.7 = 25.8$
- Divide in half: $25.8/2 = 12.9$
- $12.9 + 11.0 =$ mesiodistal width of maxillary teeth 3, 4 and 5 = 23.9
- $12.9 + 10.5 =$ mesiodistal width of mandibular teeth 3, 4 and 5 = 23.4
- Mesiodistal width of maxillary anterior teeth = 33.9
- Total maxillary tooth width = $33.9 + (23.9 \times 2) = 81.7$
- Total mandibular tooth width = $25.8 + (23.4 \times 2) = 72.6$
- Maxillary space = 79.3; mandibular space = 72.4
- Maxillary space (79.3) minus maxillary tooth material (81.7) = 2.4 mm maxillary crowding
- Mandibular space (72.4) minus mandibular tooth material (72.6) = 0.2 mm mandibular crowding

Figure 2: Models and calculation of predicted crowding in a patient in the mixed dentition stage, according to the Tanaka–Johnston method (all measurements in millimetres).

calculating the space available. This can be done using straight-line segments similar to those described above or by placing a string over the model in the projected arch form and then measuring the length of the string.

This method proved fairly reliable for a sample of northern European white children.^{1,2} Proportional tables were also accurate for populations from Egypt and northern Mexico.³ Tables are now available for a multitude of populations, such as Asian Americans, African Americans, Saudi Arabians, Jordanians, Hong Kong Chinese, Thai, Moroccans, Iranians, east Sicilians, Peruvians, South Africans, North Indians, Senegalese and Iraqis.

Tanaka–Johnston Method

In the Tanaka–Johnston method, half of the sum of the mesiodistal dimensions of the 4 mandibular incisors is calculated (in millimetres). To this value, 10.5 mm is added, and the overall sum represents an estimate of the mesiodistal dimension of the mandibular canine and premolars in one mandibular quadrant. Adding 11 mm to this value is used to estimate the mesiodistal distance of the canine and premolars of one maxillary quadrant. The tooth widths of the entire arch are then calculated and compared with the space available.

The mandibular incisor is also used in this method to estimate the mesiodistal width of unerupted teeth. The advantage of this method

is that it does not rely on radiographs or prediction tables, which may not be readily available. This method was generally accurate for northern European children, with a slight bias toward overestimation.⁴ The calculation is illustrated in **Fig. 2.** ♦

References

1. Moyers RE. Handbook of orthodontics for the student and general practitioner. Chicago: Yearbook Medical Publishers; 1973. p. 369–79.
2. Tanaka MM, Johnston LE. The prediction of the size of unerupted canines and premolars in a contemporary orthodontic population. *J Am Dent Assoc* 1974; 88(4):798–801.
3. Bishara SE, Jakobsen JR, Abdallah EM, Fernandez Garcia A. Comparisons of mesiodistal and buccolingual crown dimensions of the permanent teeth in three populations from Egypt, Mexico, and the United States. *Am J Orthod Dentofacial Orthop* 1989; 96(5):416–22.
4. Proffit WR. Contemporary orthodontics. 4th edition. St. Louis, MO: Mosby Co.; 2007. p. 195–201.

Further Reading

- Bishara SE. Textbook of orthodontics. Philadelphia, PA: W.B. Saunders Co.; 2001. p. 134–45.
- Staley RN, Kerber PE. A revision of the Hixon and Oldfather mixed-dentition prediction method. *Am J Orthod* 1980; 78(3):296–302.

THE AUTHOR



Dr. James Noble is a part-time clinical instructor in the division of orthodontics, faculty of dentistry, University of Manitoba, Winnipeg, Manitoba. He is also a staff orthodontist at Bloorview Kids Rehab in Toronto, Ontario, and maintains a private practice in orthodontics in Toronto. Email: drjamesnoble@gmail.com

QUESTION 3

The orthodontist gave my patient a rapid maxillary expander and then a functional appliance with a headgear component. The patient has achieved an outstanding result! What biological mechanism allows these appliances to work?

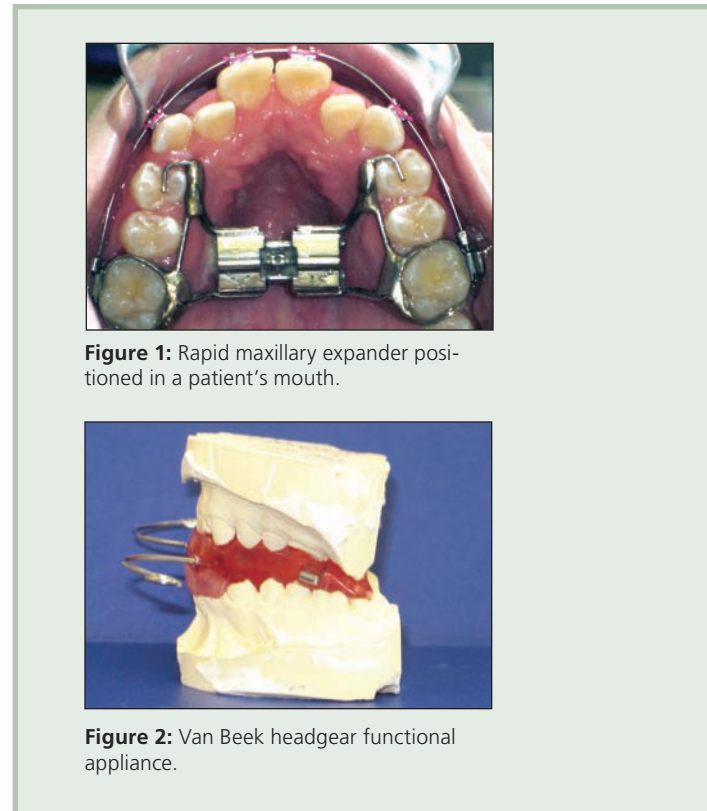
Background

The field of dentofacial orthopedics was established over 100 years ago, when Kingsley and Angle observed favourable changes with application of mechanical stresses in patients with dentofacial deformities. Since then, a plethora of orthopedic devices have been constructed in attempts to modify or alter craniofacial growth. These devices have included headgear, functional appliances and rapid maxillary expanders (RMEs) (Figs. 1 and 2).

The evidence of the clinical efficacy of these appliances is exhaustive, yet the exact mechanism of their action remains unknown. It is believed that the exogenous forces produced by these appliances result in strain on the craniofacial sutures, causing a cellular growth response.¹ Sutures are connective tissue articulations in the craniofacial bones of the skull that undergo displacement with moderate orthopedic forces and instantaneously absorb and transmit masticatory or orthopedic forces.^{2,3} Oscillatory tensile and compressive strain induces anabolic responses within the sutures and activates genes and transcription factors that stimulate growth by activating cells through mechanotransduction pathways. Growth may therefore occur in response to both hereditary and mechanical signals.¹

Craniofacial Forces from Functional Appliances

Functional appliances may also play a role in altering the function of the masticatory muscles. Stress is produced on the zygomatic, sphenoid and temporal bones through the attachments of the masseter, temporalis and lateral pterygoid muscles. These muscles are articulated by various craniofacial sutures on which they apply a load that may subsequently influence growth. It is believed that functional appliances cause stretching of the retrodiskal tissue, inducing bone formation of the fibrocartilaginous lining of the condyle and fossa and causing forces to travel along the viscoelastic tissue of the temporomandibular joints. This process may also induce bone formation at



sites distant from the retrodiskal tissue, such as the articular eminence.⁴

Craniofacial Forces from Headgear

The influence of orthodontic headgear on the nasomaxillary complex has been demonstrated by cephalometric studies showing a decrease in forward and downward growth of the maxilla.⁵ Three-dimensional finite-element analysis has identified the stress distribution of headgear, which varies depending on the direction of the force but is optimal when the force vector is closer to the centre of resistance of the maxilla.^{6,7} In photoelastic studies, the stresses were transmitted to distant craniofacial sutures.⁸ Cervical headgear placed stress on more areas and to a greater degree than high-pull headgear. The headgear affected the pterygoid plates, the zygomatic arches, the junction of the maxilla with the lacrimal bone, the

ethmoid and the maxillary teeth. Stress on the frontal process of the maxilla and the zygomatico-frontal suture was produced only by cervical headgear. Further, cervical forces tended to open the posterior palate and produced compressive stresses at the junction of the right and left maxilla, inferior to the anterior nasal spine.

Craniofacial Forces from RMEs

The goal of an RME is to produce a force that will displace the palatal suture and expand the palate. This results in application of forces to the maxilla and adjacent structures. Histologic studies of expansion in animals demonstrated increased cellular activity at the nasal, maxillary-zygomatic and zygomaticotemporal sutures, with the greatest activity at the nasal suture.⁹⁻¹³

Photoelastic studies of the human skull showed stress in the anterior region of the palate, which progressed posteriorly and radiated superiorly to areas along the perpendicular plates of the palatine bone, deeper to anatomic structures such as the lacrimal, nasal and malar bones, the pterygoid plates of the sphenoid, the zygomatic process and the medial wall of the orbit.¹⁴

Three-dimensional finite-element analysis of a young dry skull revealed lateral displacement at the region of the upper central incisors and lateral displacement at the inferior aspect of the pterygoid plates.¹⁵ The pterygoid plates approximating the cranial base were minimally displaced. Midline structures experienced a downward displacement, with cephalometric landmarks ANS and A point moving down. The expansive forces were distributed throughout the craniofacial skeleton.

Conclusions

Orthopedic loading results in the transmission of forces that produce tensile and compressive strain on the craniofacial sutures, which then absorb and transmit these forces. Different sutures experience different stresses and strain, and their bony edges become displaced, either through tension or compression. This can result in modulation of sutural growth at the cellular level, leading to overall growth modification. ♦

References

1. Mao JJ. Mechanobiology of craniofacial sutures. *J Dent Res* 2002; 81(12):810-6.
2. Kragt G, Duterloo HS. The initial effects of orthopedic forces: a study of alterations in the craniofacial complex of a macerated human skull owing to high-pull headgear traction. *Am J Orthod* 1982; 81(1):57-64.

3. Kragt G, Duterloo HS, Algra AM. Initial displacements and variations of eight human child skulls owing to high-pull headgear traction determined with laser holography. *Am J Orthod* 1986; 89(5):399-406.
4. Voudouris JC, Woodside DG, Altuna G, Angelopoulos G, Bourque PJ, Lacouture CY, and other. Condyle-fossa modifications and muscle interactions during Herbst treatment, Part 2. Results and conclusions. *Am J Orthod Dentofacial Orthop* 2003; 124(1):13-29.
5. Barton JJ. High-pull headgear versus cervical traction: a cephalometric comparison. *Am J Orthod* 1972; 62(5):517-29.
6. Tanne K, Matsubara S, Sakuda M. Stress distributions in the maxillary complex from orthopedic headgear forces. *Angle Orthod* 1993; 63(2):111-8.
7. Tanne K, Matsubara S. Association between the direction of orthopedic headgear force and sutural responses in the nasomaxillary complex. *Angle Orthod* 1996; 66(2):125-30.
8. Chaconas SJ, Caputo AA, Davis JC. The effects of orthopedic forces on the craniofacial complex utilizing cervical and headgear appliances. *Am J Orthod* 1976; 69(5):527-39.
9. Starnbach HK, Cleall JF. The effects of splitting the midpalatal suture on the surrounding structures. *Am J Orthod* 1964; 50:923-4.
10. Starnbach H, Bayne D, Cleall J, Subtelny JD. Facioskeletal and dental changes resulting from rapid maxillary expansion. *Angle Orthod* 1966; 36(2):152-64.
11. Gardner GE, Kronman JH. Cranioskeletal displacements caused by rapid palatal expansion in the Rhesus monkey. *Am J Orthod* 1971; 59(2):146-55.
12. Storey E. Tissue response to the movement of bones. *Am J Orthod* 1973; 64(3):229-47.
13. Ten Cate AR, Freeman E, Dickinson JB. Sutural development: structure and its response to rapid expansion. *Am J Orthod* 1977; 71(6):622-36.
14. Chaconas SJ, Caputo AA. Observation of orthopedic force distribution produced by maxillary orthodontic appliances. *Am J Orthod* 1982; 82(6):492-501.
15. Jafari A, Shetty S, Kumar M. Study of stress distribution and displacement of various craniofacial structures following application of transverse orthopedic forces – a three-dimensional FEM study. *Angle Orthod* 2003; 73(1):12-20.

THE AUTHORS



Dr. James Noble is a part-time clinical instructor in the division of orthodontics, faculty of dentistry, University of Manitoba, Winnipeg, Manitoba. He is also a staff orthodontist at Bloorview Kids Rehab in Toronto, Ontario, and maintains a private practice in orthodontics in Toronto. Email: drjamesnoble@gmail.com



Dr. Nicholas E. Karaiskos maintains a private practice in orthodontics in Ottawa, Ontario.



Dr. William A. Wiltshire is a professor in and head of orthodontics and head of the department of preventive dental sciences, University of Manitoba, Winnipeg, Manitoba.

QUESTION 4

Should I be concerned if a patient requiring orthodontic treatment has an allergy to nickel?

Background

Nickel is present in a vast array of materials frequently used in orthodontics. It is the most common component of the super-elastic nickel–titanium archwires, it is a component in stainless steel (which is present in both archwires and brackets), and it is present in extra-oral appliances such as the outer bows of headgear. At the same time, nickel allergy is common in the general population. An estimated 11% of all women and 20% of women between the age of 16 and 35 years are affected¹⁻³; nickel allergy is present in only 2% of males, probably because of less contact with nickel in jewellery. Nickel sensitivity is a growing concern in dental practice because of recent increases in the use of oral piercings and jewellery.

The concentration of nickel required to elicit an allergic reaction is much greater in the oral mucosa than in the skin.⁴ Therefore, most people who have nickel sensitivity do not report adverse clinical reactions to orthodontic appliances that contain nickel, and the rate of harmful response to nickel has been estimated at only 0.1%–0.2%.⁵ In addition, orthodontic appliances have low levels of nickel leaching and high resistance to corrosion.

Immune Response

Nickel usually elicits a type IV cell-mediated delayed hypersensitivity that is also called allergic contact dermatitis. This reaction is mediated by T cells, monocytes and macrophages, rather than antibodies. The reaction begins with a sensitization phase, when the nickel initially enters the body. This usually results in no response, but it primes or sensitizes the immune system. The second phase, elicitation, occurs during re-exposure and results in contact mucositis or dermatitis, which develops over days or, rarely, up to 3 weeks. Nickel leaching from orthodontic appliances can cause this type IV hypersensitivity.

Diagnosis

Diagnosis of an oral response to nickel is more difficult than diagnosis of a skin response. Information about nickel allergy should be elicited at the initial appointment, either through the medical questionnaire or during a verbal medical

history. Any patient who reports a history of nickel allergy should be advised of a possible response to the nickel in orthodontic appliances, particularly after placement of the first archwire. If nickel allergy is in question, a dermatologist can perform a cutaneous sensitivity test called a patch test, using 5% nickel sulphate in petroleum jelly.⁶

Oral clinical signs and symptoms of nickel allergy include a burning sensation, gingival hyperplasia, labial desquamation, angular cheilitis, erythema multiforme, periodontitis, stomatitis with mild to severe erythema, papular perioral rash, loss of taste or a metallic taste, or numbness and soreness at the side of the tongue. Intraoral symptoms can occur without signs, and extra-oral manifestations of nickel allergy may have an intraoral origin. Before nickel hypersensitivity can be diagnosed, other possible causes, such as candidiasis, herpetic stomatitis, ulcers due to mechanical irritation and allergies to other materials (including acrylic), should be eliminated.

Treatment

If a diagnosis of nickel allergy is confirmed and intraoral signs and symptoms are present, the nickel titanium archwire should be removed and replaced with a stainless steel archwire, which is low in nickel content. A titanium–molybdenum alloy, which contains no nickel, can also be used. Orthodontic treatment with such archwires can be effective, but there may be increases in operator chair time, number of appointments required and overall treatment time. These differences are attributed to greater difficulty in the initial leveling and aligning stages of treatment and the potential need to bend the wires, which do not have the shape-memory and super-elastic properties of nickel–titanium archwires. Manufacturers claim that resin-coated nickel–titanium wires have lower resistance to corrosion, and these are also an option. However, there are no reports in the literature of clinical use of these products for patients with confirmed intraoral nickel allergy.

Most patients who have a reaction to nickel–titanium archwires have no reaction to stainless steel,⁷ probably because the nickel in stainless steel is tightly bound to the crystal lattice, which prevents leaching into the mouth. If, after placement

of stainless steel archwires, the patient continues to experience an allergic reaction, all stainless steel archwires and brackets should be removed; however, this situation is rare. Orthodontic treatment should be continued with titanium–molybdenum alloy or fibre-reinforced composite archwires and brackets made of titanium, gold, ceramic or polycarbonate. For less complex cases, the use of aligners such as Invisalign (Align Technology, Inc., Santa Clara, Calif.) can be another treatment alternative.

Conclusions

Dermatologic allergy to nickel is common, particularly among women. However, an allergic response in the oral cavity (or even in other parts of the body) because of nickel in orthodontic appliances is rare. If clinical signs and symptoms develop, the practitioner should be prepared to continue orthodontic treatment without using nickel–titanium archwires or stainless steel. ✦

References

1. Nielson NH, Menné T. Allergic contact sensitization in an unselected Danish population. The Glostrup Allergy Study, Denmark. *Acta Derm Venereol* 1992; 72(6):456–60.
2. Nielson NH, Menné T. Nickel sensitization and ear piercing in an unselected Danish population. The Glostrup Allergy Study. *Contact Dermatitis* 1993; 29(1):16–21.
3. Menné T. Prevention of nickel allergy by regulation of specific exposures. *Ann Clin Lab Sci* 1996; 26(2):133–8.
5. Menné T. Quantitative aspects of nickel dermatitis. Sensitization and eliciting threshold concentrations. *Sci Total Environ* 1994; 148(2-3):275–81.
4. Dunlap CL, Vincent SK, Barker BF. Allergic reaction to orthodontic wire: report of a case. *J Am Dent Assoc* 1989; 118(4):449–50.
6. Menné T, Brandup F, Thestrup-Pedersen K, Veien NK, Andersen JR, Yding F, and other. Patch test reactivity to nickel alloys. *Contact Dermatitis* 1987; 16(5):255–9.
7. Toms AP. The corrosion of orthodontic wire. *Eur J Orthod* 1988; 10(2):87–97.

Additional Reading

- Bass JK, Fine H, Cisneros GJ. Nickel hypersensitivity in the orthodontic patient. *Am J Orthod Dentofacial Orthop* 1993; 103(3):280–5.
- de Silva BD, Doherty VR. Nickel allergy from orthodontic appliances. *Contact Dermatitis* 2000; 42(2):102–3.
- Fleming CJ, Burden AD, Forsyth A. The genetics of allergic contact hypersensitivity to nickel. *Contact Dermatitis* 1999; 41(5):251–3.
- Noble J, Ahing SI, Karaikos NE, Wiltshire WA. Nickel allergy and orthodontics, a review and report of two cases. *Br Dent J* 2008; 204(6):297–300.
- Rahilly G, Price N. Nickel allergy and orthodontics. *J Orthod* 2003; 30(2):171–4.
- Setcos JC, Babaei-Mahani A, Silvio LD, Mjör IA, Wilson NH. The safety of nickel containing dental alloys. *Dent Mater* 2006; 22(12):1163–8. Epub 2006 Jan 6.
- Wiltshire WA, Ferreira MR, Ligthelm AJ. Allergies to dental materials. *Quintessence Int* 1996; 27(8):513–20.

THE AUTHORS



Dr. James Noble is a part-time clinical instructor in the division of orthodontics, faculty of dentistry, University of Manitoba, Winnipeg, Manitoba. He is also a staff orthodontist at Bloorview Kids Rehab in Toronto, Ontario, and maintains a private practice in orthodontics in Toronto. Email: drjamesnoble@gmail.com



Dr. Stephen I. Ahing is an associate professor and a specialist in oral medicine and pathology, division of oral diagnosis and radiology, University of Manitoba, Winnipeg, Manitoba.



Dr. Nicholas E. Karaikos maintains a private practice in orthodontics in Ottawa, Ontario.



Dr. William A. Wiltshire is a professor in and head of orthodontics and head of the department of preventive dental sciences, University of Manitoba, Winnipeg, Manitoba.